

Review

Equine herpesvirus-1 myeloencephalopathy: A review of recent developments

Nicola Pusterla^{a,*}, W. David Wilson^a, John E. Madigan^a, Gregory L. Ferraro^b

^a Department of Medicine and Epidemiology, School of Veterinary Medicine, University of California, One Shields Avenue, Davis, CA 95616, USA

^b Center for Equine Health, School of Veterinary Medicine, University of California, Davis, CA 95616, USA

Accepted 8 August 2008

Abstract

Equine herpes myeloencephalopathy (EHM), although a relatively uncommon manifestation of equine herpesvirus-1 (EHV-1) infection, can cause devastating losses on individual farms or boarding stables. Although outbreaks of EHM have been recognized for centuries in domestic horse populations, many aspects of this disease remained poorly characterized. In recent years, an improved understanding of EHM has emerged from experimental studies and from data collected during field outbreaks at riding schools, racetracks and veterinary hospitals throughout North America and Europe. These outbreaks have highlighted the contagious nature of EHV-1 and have prompted a re-evaluation of diagnostic procedures, treatment modalities, preventative measures and biosecurity protocols for the disease. This review concentrates on these and other selected, clinically relevant aspects of EHM.

© 2008 Elsevier Ltd. All rights reserved.

Keywords: Equine herpes virus (EHV)-1; Equine herpes myeloencephalopathy (EHM); Diagnosis; Treatment; Prevention; Biosecurity

Introduction

Equine herpesvirus-1 (EHV-1) is an important, ubiquitous equine viral pathogen that exerts its major impact by inducing abortion storms or sporadic abortions in pregnant mares, early neonatal death in foals, respiratory disease in young horses and myeloencephalopathy (Jackson et al., 1977; Peet et al., 1978; Ostlund, 1993; Van Maanen, 2002; Reed and Toribio, 2004; Patel and Heldens, 2005). Although equine herpesvirus-1 myeloencephalopathy (EHM) is a sporadic and relatively uncommon manifestation of EHV-1 infection, it can cause devastating losses and have a severe impact on the equine industry, as exemplified by recent outbreaks at riding schools, racetracks and veterinary hospitals throughout North America and Europe (Kohn et al., 2006; Henninger et al., 2007).

The neurological signs of EHM reflect a diffuse, multifocal myeloencephalopathy secondary to vasculitis, hemorrhage, thrombosis and ischemic neuronal injury (Edington et al., 1986; Wilson, 1997). The sudden onset and early manifestation of ataxia, paresis and urinary incontinence, the involvement of multiple horses on the premises, and a recent history of fever, abortion or respiratory disease in affected horse populations are typical features, although there is considerable variation between outbreaks with respect to epidemiological and clinical findings (Wilson, 1997). Prevention is difficult because many horses are latently infected, allowing the virus to circulate silently in horse populations, and currently available vaccines do not confer protection against neurological manifestations of infection (Patel and Heldens, 2005; Slater, 2007). Although outbreaks of EHM have been recognized for centuries among domestic horse populations, many aspects of the disease remain poorly characterized. Selected and clinically relevant aspects of EHM, such as diagnostic work-up, treatment, prevention and biosecurity, are reviewed in this article.

* Corresponding author. Tel.: +1 530 754 5523; fax: +1 530 752 9815.
E-mail address: npusterla@ucdavis.edu (N. Pusterla).

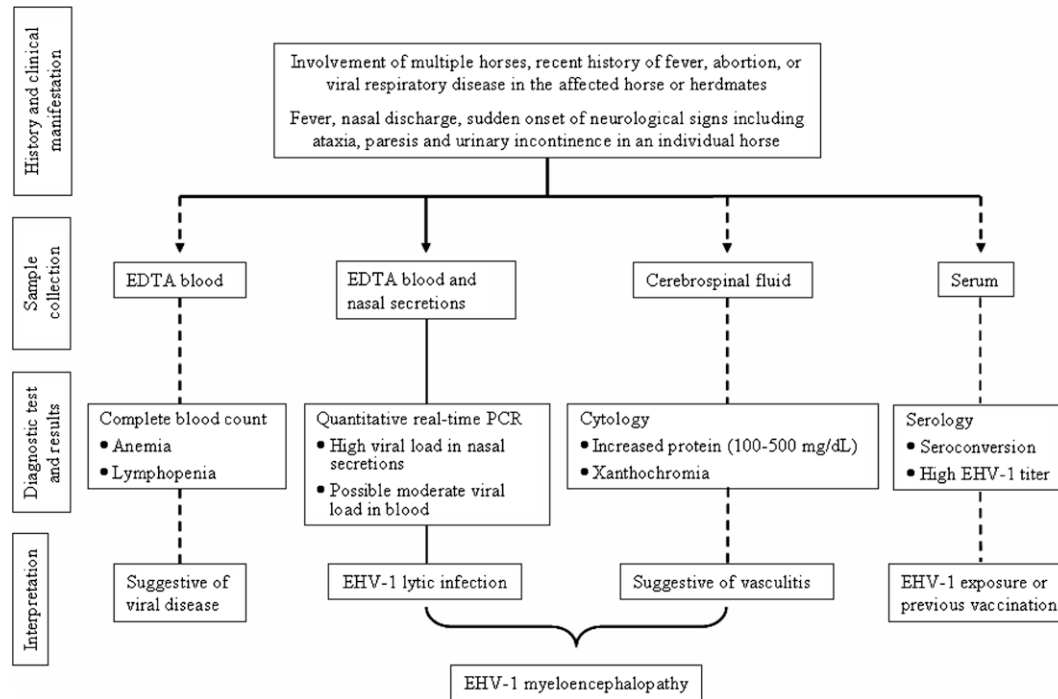


Fig. 1. Algorithm to establish a rapid ante-mortem laboratory diagnosis of EHV-1 infection in a horse with neurological deficits. Dashed arrows represent a presumptive, and solid arrows a diagnostic pathway.

Diagnosis

The multifocal distribution of lesions caused by neurotropic EHV-1 strains results in considerable variability in clinical presentation and a number of conditions should be included in the differential diagnosis. These include equine protozoal myeloencephalitis, cervical stenotic myelopathy, cervical vertebral instability ('wobbler' syndrome), cervical vertebral fracture or other central nervous system (CNS) trauma, neuritis of the cauda equina, fibrocartilaginous infarction, aberrant parasite migration, degenerative myelopathy, togaviral encephalitis (flaviviruses and alphaviruses), rabies, botulism, CNS abscessation and a variety of plant and chemical intoxications (Kohn and Fenner, 1987; Wilson and Pusterla, 2004).

The sudden onset of neurological signs, including ataxia, paresis and urinary incontinence, the involvement of multiple horses and a recent history of fever, abortion, or respiratory disease in an affected horse population are sufficient to make a tentative diagnosis of EHM (Fig. 1). Pyrexia has consistently been reported as the major clinical sign before the onset of neurological disease but is frequently not present by the time neurologic deficits become apparent (Friday et al., 2000; Van Maanen et al., 2001; Henninger et al., 2007).

Definitive ante-mortem diagnosis of EHM is frequently not possible, since as test results lack consistency. However, a diagnosis can be supported by ruling out other conditions, demonstrating xanthochromia and an elevated cerebrospinal fluid (CSF) protein concentration, in identifying or isolating EHV-1 from the respiratory tract, buffy

coat or CSF and in demonstrating a 4-fold increase in antibodies using serum neutralizing (SN), complement fixation (CF), or ELISA tests performed on acute and convalescent serum from affected or in-contact horses 7–21 days apart (Blythe et al., 1985; Friday et al., 2000; Van Maanen et al., 2001).

Hematological abnormalities in horses with EHM are inconsistent and may include mild anemia and lymphopenia in the early stages, followed a few days later by mild hyperfibrinogenemia (Paradis, 1996; Wilson, 1997). Azotemia and hyperbilirubinemia may occur secondary to dehydration and anorexia, respectively.

CSF analysis typically, although not always, reveals xanthochromia, an increased protein concentration (100–500 mg/dL), and an increased albumin quotient (ratio of CSF to serum albumin concentration), which reflects vasculitis with protein leakage into the CSF. The nucleated cell count in the CSF is usually normal (0–5 cells/ μ L) but is occasionally increased (Jackson and Kendrick, 1971; Kohn and Fenner, 1987; Donaldson and Sweeney, 1998; Wilson and Pusterla, 2004). Abnormalities in the CSF are not present at the onset of clinical signs in some horses and changes resolve quickly, so that the CSF may be normal within 2 weeks of the onset of clinical signs.

The presence of antibodies against EHV-1 in the CSF of clinically affected horses is strongly suggestive of EHM, although antibodies are absent in many cases (Jackson et al., 1977; Kohn and Fenner, 1987; Keane et al., 1988). The albumin and immunoglobulin (Ig)G concentrations and EHV-1 antibody titer in both serum and CSF should be taken into account when interpreting CSF antibody

results. Since the albumin quotient is usually elevated in affected horses and the IgG index is normal, the presence of EHV-1 antibodies in the CSF reflects leakage of protein across a damaged blood–brain or blood–CSF barrier secondary to vasculitis rather than intra-theal antibody production (Klingeborn et al., 1983; Keane et al., 1988). Antibodies are, therefore, more likely to be present in the CSF of affected horses with concomitantly high serum titers.

Blood contamination during collection of CSF, and other diseases that cause an increase in the permeability of the blood–brain barrier or bleeding into the subarachnoid space, may falsely elevate CSF antibody titers if serum titers are also high. The detection by molecular methods or the isolation of EHV-1 from the CSF of affected horses will confirm a diagnosis but is rarely successful.

Virus isolation is considered the ‘gold standard’ test for a laboratory diagnosis of EHV-1 infection and should be attempted, especially during epidemics of EHM, concurrent with use of rapid diagnostic tests such as the polymerase chain reaction (PCR), in order to achieve retrospective biological and molecular characterization of the viral isolate. Isolation and identification of EHV-1 from nasal or nasopharyngeal swabs or buffy coat samples is strongly supportive of a diagnosis of EHM in a horse with compatible clinical signs. This requires submission of nasal or nasopharyngeal swabs in viral transport medium and an uncoagulated blood sample.

Results of virus isolation may, however, be negative because the peak of virus shedding has usually passed by the time neurological signs appear, virus may be shed intermittently and local antibodies may interfere with virus recovery (Mumford, 1984). The likelihood of isolating EHV-1 during outbreaks of neurological disease is increased by monitoring in-contact horses and collecting nasal or nasopharyngeal swab and buffy coat samples from these animals during the prodromal febrile phase before neurological signs develop. However, it must also be considered that the interpretation of positive viral cultures can be confused, given that EHV-1 has been isolated from the respiratory tract of healthy horses.

Rapid laboratory tests for detection of EHV-1 are most useful in potential epidemics, because rapid identification of the causative agent is often critical for guiding management strategies. PCR has become the diagnostic test of choice due to its high sensitivity and specificity and PCR detection of EHV-1 is routinely performed on secretions from nasal or nasopharyngeal swabs or from uncoagulated blood samples. Many conventional PCR detection protocols using single or nested methods and targeting specific EHV-1 genes have been published in recent years (Ballagi-Pordany et al., 1990; Sharma et al., 1992; Wagner et al., 1992; Borchers and Slater, 1993; Kirisawa et al., 1993; Lawrence et al., 1994). Although considerable progress has been made in developing PCR assays, the lack of laboratory protocol standardization and quality assurance procedures remain ongoing challenges.

The increasing application of PCR in EHV-1 detection in practice settings has presented new dilemmas in test interpretation, since such assays are unable to differentiate between replicating (lytic), non-replicating or latent virus. Advances in technology and the use of novel PCR platforms, such as real-time PCR (RT-PCR), enable the quantification of viral loads for equine herpesviruses (Pusterla et al., 2005, 2006; Allen and Breathnach, 2006; Diallo et al., 2006; Elia et al., 2006; Hussey et al., 2006). Viral load testing, although not routinely offered by many veterinary laboratories, represents a major advancement in the diagnosis of EHV-1 infection, as it allows better characterization of disease stage, better assessment of risk of exposure of in-contact horses, and better monitoring of response to therapy. RT-PCR has recently been used to document differences in EHV-1 viral loads in blood and nasal secretions between horses in the febrile and neurological stages of disease and between clinical and subclinical cases (Pusterla et al., 2008a). These studies found high viral loads in the nasal secretions of animals with neurological signs, confirming their importance as a potential source of contagion for other horses, and highlighting the need to impose strict biosecurity when horses are identified with suspected or confirmed EHM.

However, random testing of clinically normal horses for EHV-1 by PCR should be avoided, since practicing veterinarians and regulatory officials, on receipt of positive test results, may be unaware of the complexities involved in test interpretation, leading to inappropriate decision-making in relation to the quarantine of equine facilities or the cancellation of competitions. However, the situation is somewhat different when healthy horses, at high risk of exposure, are tested during an outbreak of clinical EHV-1 infection. Under such circumstances, horses that test positive by PCR on nasal or nasopharyngeal secretions should be isolated and closely monitored for the development of clinical signs, since the viral load affecting animals during the early incubation period is similar to that of subclinical carriers (Pusterla et al., 2008b).

Follow-up assessment of viral loads in blood and nasal or nasopharyngeal secretions can guide modifications to control measures, including the lifting of quarantine for individual horses that test negative on subsequent sampling. It should be noted that exposed but latently infected horses may test positive for EHV-1 but never exhibit clinical disease following exposure to an index case. Such latently infected horses may continue to test positive for extended periods of time, thus further confusing their clinical evaluation and confounding control procedures for in-contact horses.

A recently identified variable region in the EHV-1 genome correlates with neurological disease (Nugent et al., 2006). This sequence variation occurs in the DNA polymerase gene (ORF 30) involved in initial viral replication within cells. PCR assays based on ORF 30 have recently been developed and used to differentiate between EHV-1 isolates from neurologically and non-neurologically

affected horses (Allen, 2007; Leutenegger et al., 2008). However, the genotyping of field isolates needs to be interpreted carefully, since between approximately 14% and 24% of EHV-1 isolates from horses with EHM do not have this neuropathogenic marker (Nugent et al., 2006; Perkins et al., 2008). Strain characterization may be important however, given that the odds of neurological disease when infected with the neurotropic EHV-1 genotype versus the non-neurotropic genotype are 162 times greater (Perkins et al., 2008). Furthermore, detection of a neurotropic EHV-1 strain may influence therapy, especially the use of anti-viral drugs, such as valacyclovir, used to decrease viremia and prevent the development of neurological sequelae.

Serology that demonstrates a 4-fold or greater increase in serum antibody titer, using SN or CF tests, on acute and convalescent samples collected 7–21 days apart provides presumptive evidence of infection (Mumford, 1984; McCartan et al., 1995; Friday et al., 2000; Van Maanen et al., 2001). Many horses with EHM, however, do not exhibit a 4-fold rise in SN titer, since titers rise rapidly and may have peaked by the time neurological signs appear (Jackson and Kendrick, 1971; Jackson et al., 1977; Mumford, 1984; McCartan et al., 1995; Friday et al., 2000; Van Maanen et al., 2001). Although serology is limited in confirming EHM in an individual horse, testing of paired serum samples from in-contact animals is recommended given that a significant proportion of these animals seroconvert, providing indirect evidence of EHV-1 infection. Interpretation of serology is complicated by the fact that the SN, CF and ELISA tests in use at most diagnostic laboratories do not distinguish between antibodies to EHV-1 and -4. A specific ELISA based on the C-terminal portion of glycoprotein G of both viruses has been developed and should prove valuable in the investigation and management of disease outbreaks in the future (Crabb and Studdert, 1993; Crabb et al., 1995; Drummer et al., 1995).

Histopathological examination of the brain and spinal cord is essential in confirming EHV-1 infection in a horse with suspected EHM. Vasculitis and thrombosis of small blood vessels in the spinal cord or brain are consistent histopathological changes (Whitwell et al., 1992) and virus detection in the CNS is achieved using immunohistochemistry, in situ hybridization and PCR (Schmidt et al., 1994; Leutenegger et al., 2008).

Thus, molecular assays have supplanted more cumbersome and time-consuming diagnostic modalities in the routine diagnosis of EHV-1 infection. One of the main drawbacks of the PCR method has been the lack of standardized protocols and the need for a consensus on the interpretation of the results. It is suggested that diagnostic laboratories should consider reporting quantitative information regarding PCR EHV-1 viral loads in blood and nasopharyngeal secretions, since this may influence the risk of exposure of other horses and may help practitioners and regulatory officials make appropriate decisions regarding the management of horses that test positive. Furthermore, the detection of viral transcripts for 'late' genes may facil-

itate the differentiation of lytic and latent infection and the use of PCR assays that determine viral genotype will help in assessing the risk of an animal developing EHM following exposure. Although molecular detection techniques have become more complex in their interpretation, the information gleaned from such methods will help prevent disease spread and maximize treatment options for affected animals.

Treatment

The treatment of EHM is challenging and the outcome is directly related to the severity of the neurological deficits in the affected horse. As no specific treatment is available, the management of affected animals is directed towards supportive nursing and nutritional care and in reducing CNS inflammation.

Non-recumbent horses should be encouraged to stand and should be protected from self-inflicted trauma by the provision of good footing (such as a grass paddock), by placement of food and water in accessible locations at a convenient height above ground level and by other measures, including the use of padded hoods and the removal of obstacles. Patients that become recumbent should be maintained in a sternal position on a thick cushion of dry absorbent bedding and should be rolled at least every 2–4 h to reduce the risk of developing myonecrosis and decubital ulcers. Whenever possible, animals should be lifted to, and supported in, the standing position using an appropriately fitted sling. Slings are most beneficial for moderately affected horses that are too weak to rise but are able to maintain a standing position with minimal assistance.

Affected horses usually maintain a good appetite, even when recumbent, although hand feeding may be necessary to encourage some animals to eat. Maintenance of hydration is important, and provision of a laxative diet or the administration of laxatives, such as bran mashes, mineral oil, or psyllium, may be necessary to reduce intestinal impaction. The nutritional and hydration needs of anorectic patients can usually be met by feeding gruels of alfalfa-based or similar pelleted feeds in water or balanced electrolyte solutions via nasogastric tube. If oral intake is insufficient to meet hydration requirements of 60–80 mL/kg bodyweight per day, hydration can be maintained by the intravenous (IV) administration of balanced electrolyte solutions. Partial or total parenteral nutrition can also be used to address the caloric needs of anorectic recumbent horses.

If affected horses are unable to stand and urinate, or if bladder function is significantly impaired, manual evacuation of the bladder by application of pressure per rectum may be necessary. If these measures are unsuccessful, judicious urinary catheterization is indicated and should be performed aseptically with the collection tubing attached to a sterile closed bag in order to minimize the risk of urinary tract infection. Urine scalding can become a major problem, particularly in mares 'dribbling' urine. Prevention

of such scalding involves the regular washing of the perineum, tail and hind legs with water, the application of water-repellent ointments and the braiding or wrapping of the tail to simplify cleaning. Administration of enemas or manual emptying of the rectum may also be necessary to promote defecation and improve patient comfort.

The medical treatment of horses with EHM focuses mainly on decreasing the inflammation associated with the induced vasculitis. Recommended drugs routinely used in the treatment of EHM are listed in Table 1. Since the vasculitis, hemorrhage and edema, which are prominent early lesions of EHM, may have an immunological basis, early treatment with corticosteroids is recommended. However, no objective data are available to validate the efficacy of these or other anti-inflammatory drugs, and the use of corticosteroids remains controversial. A short course of treatment with corticosteroids, such as prednisolone acetate or dexamethasone, for 2–3 days is frequently recommended for severely affected animals (Kohn and Fenner, 1987; Wilson, 1997) (Table 1).

The non-steroidal anti-inflammatory flunixin meglumine is indicated for treatment of CNS vasculitis and is typically used to treat EHM. Dimethyl sulfoxide (DMSO) administered IV as a 10–20% solution in normal saline or in 5% dextrose once daily for up to 3 days is commonly used to treat horses with suspected CNS trauma or inflammatory disease, such as EHM (Henninger et al., 2007). Although the efficacy of DMSO in the treatment of EHM has not been evaluated, its reported ability to inhibit platelet aggregation and scavenge free-radicals supports its continued use.

Because of the high risk of developing cystitis and other secondary bacterial infections, it is advisable to administer broad-spectrum antimicrobials, such as potentiated sulfonamides or ceftiofur, particularly when accompanying corticosteroid treatment. The choice of antimicrobials for the treatment of secondary bacterial infection of the urinary

tract, respiratory tract or other areas should be based on the results of culture and susceptibility testing.

Acyclovir, a synthetic purine nucleoside analog with inhibitory activity against several human herpesviruses, has recently been used in the treatment and prevention of EHV-1 infection. The efficacy of acyclovir has been demonstrated in vitro with inhibitory concentrations of 0.3–7.0 µg/mL effective against neurotropic and non-neurotropic EHV-1 isolates (Rollinson and White, 1983; Smith et al., 1983; Wilkins, 2004; Garré et al., 2007a). There are, however, limited data describing the in vivo efficacy of acyclovir against EHV-1 infection and controlled clinical studies have yet to be carried out. The apparent benefit of acyclovir therapy is supported by the successful treatment of congenital EHV-1 infection (Murray et al., 1998; Friday et al., 2000) and by a reduction in the incidence of EHM in horses treated prophylactically with acyclovir during recent outbreaks (Henninger et al., 2007). Pharmacokinetic studies in adult horses with single oral administrations of 10 and 20 mg/kg of acyclovir indicated poor bioavailability of the drug (2.8%) and great variability in serum acyclovir-time profiles (Bentz et al., 2006). This has raised questions about its use and, although IV administration at 10 mg/kg theoretically produces therapeutic concentrations, the high cost and lack of practicality may limit its routine IV use (Wilkins et al., 2005; Bentz et al., 2006).

The primary route of elimination of acyclovir is renal, and some human patients with renal failure have developed adverse effects, primarily manifested as neurological disturbances (Adair et al., 1994). Therefore, renal function should be monitored and maintained when administering the drug. Recent preliminary data indicate that another nucleoside analog, valacyclovir, may have promise in both the treatment of EHV-1-affected horses and in the prophylaxis and containment of EHV-1 outbreaks (Bentz et al., 2007; Garré et al., 2007b). The bioavailability of the pro-

Table 1
Drugs commonly used in the treatment of equine herpesvirus-1 myeloencephalopathy

Drug	Dosage(s) ^a	Regiment, route and duration of treatment ^a
<i>Anti-inflammatories</i>		
Flunixin meglumine	1.1 mg/kg	Twice daily, PO, IM or IV, for 3–5 days
Dexamethasone	0.05–0.25 mg/kg	Daily, IM or IV, for 3 days
Prednisolone acetate	1–2 mg/kg	Daily, PO, for 3 days
<i>Free-radical scavengers</i>		
Dimethyl sulfoxide (DMSO)	0.5–1 g/kg	Daily, IV or PO, for 3 days
<i>Antimicrobials</i>		
Trimethoprim–sulfamethoxazole	30 mg/kg	Twice daily, PO, for 5–7 days
Ceftiofur	2.2 mg/kg	Once to twice daily, IM or IV, for 5–7 days
<i>Antitherapeutic drugs</i>		
Acyclovir	10–20 mg/kg	Three to five times daily, PO, for 7 days
Valacyclovir	30–40 mg/kg	Twice to three times daily, PO, for 7 days

IM: intramuscular, IV: intravenous, PO: per os.

^a Dosage, regiment, route and duration of treatment represent a compilation of published data.

drug valacyclovir is in the order of 35–40% and has been administered per os at 30 mg/kg twice daily, to facilitate treatment compliance. However, experimental studies are needed to define the appropriate doses of valacyclovir and acyclovir in horses and to document their efficacy in the treatment of EHM.

Affected horses that remain standing have a good prognosis, and improvement is generally apparent within a few days. Several weeks to more than a year may be required before horses with severe neurological deficits completely recover. Some horses may be left with permanent residual neurological deficits, including urinary incontinence and ataxia.

Prevention

Following recent outbreaks of EHM in horse populations in several regions of North America, many racing jurisdictions and managers of equine facilities and events have imposed EHV-1 vaccination requirements for incoming and resident horses in the hope that EHV-1 infection and the development of EHM can be prevented. The merits of such an approach remain unproven and, in fact, frequent revaccination of mature horses to prevent EHM is not clearly justified in most circumstances given that EHM is a relatively rare disease from a population perspective, most mature animals have previously been infected with EHV-1 and are latent carriers and none of the currently available EHV-1 or EHV-4 vaccines claim to prevent EHM.

Currently available vaccines do not reliably block infection, the development of viremia or the establishment of latency and EHM has been observed in horses regularly vaccinated against EHV-1 at 3–5 monthly intervals with inactivated or modified-live vaccines (MLV); (Kohn and Fenner, 1987; Wilson, 1991; Friday et al., 2000; Henninger et al., 2007). Furthermore, vaccination has been cited as a potential risk factor for the development of EHM, although the supporting evidence is far from conclusive. In contrast, field experience in North America strongly suggests that regular revaccination of pregnant mares and other horses on breeding farms reduces the risk of EHV-1 induced abortion and is thus justified (Ostlund, 1993).

Although there is no reliable method of preventing EHM, implementation of routine management practices aimed at reducing the likelihood of introducing and disseminating EHV-1 infection is justified (Mumford, 1985; Allen and Bryans, 1986). New arrivals should be isolated for at least 3 weeks before joining the herd, distinct herd groups should be maintained based on their age and use, and care should be taken to minimize or eliminate contact between resident and transient horses. In particular, pregnant broodmares should be maintained in groups separate from the remaining population. In addition, it is prudent to minimize stress associated with overcrowding and handling procedures in an attempt to reduce recrudescence of latent EHV-1 infection.

As with other herpesviruses, the ability of EHV-1 to infect horses and establish a long-term latent-carrier state in the face of the host immune responses assures indefinite endemic EHV-1 infection in the equine population. Resistance to re-infection resulting from recovery from field infection with EHV-1 is short-lived, lasting only a few weeks to a few months. After infecting the horse via the respiratory tract, EHV-1 rapidly becomes intracellular, including within circulating lymphocytes, and passes directly from cell to cell without an extracellular phase so that the virus is not exposed to neutralizing antibodies and other protective components of the immune response. In order to be effective, EHV-1 vaccines must satisfy a challenging set of demands and activate a protective response that exceeds that provoked by natural infection.

An ideal EHV-1 vaccine would not only be safe and lend itself to efficient delivery, it would also invoke strong, persistent local humoral (virus neutralizing antibody) and cellular (cytotoxic T-lymphocyte; CTL) responses at the respiratory mucosal surface in order to block infection (Slater, 2007). In addition, such a vaccine would be required to induce durable systemic humoral and CTL responses to rapidly clear free virus and to destroy virus-infected cells in the event that the mucosal response did not prevent systemic infection (Slater, 2007). Beyond that, the ideal vaccine would need to induce this broad spectrum of responses in young foals to protect them against field challenge that inevitably occurs during their first 2 years and leads to a chronic latent-carrier state (Slater, 2007). Not surprisingly, currently available vaccines fall short of these ideals.

Of the 17 vaccines containing an EHV-1 antigen marketed in North America or Europe, 15 are inactivated whole virus vaccines and two are MLV. All are administered by IM injection, 15 are licensed to aid the prevention of respiratory disease, and three (all inactivated) are licensed to aid the prevention of abortion (Patel and Heldens, 2005). The EHV-1 vaccines currently marketed in North America include two single-component inactivated vaccines, namely Pneumabort K-1B (Fort Dodge) and Prodigy (Intervet), that are licensed for the prevention of abortion in pregnant mares, several multi-component inactivated vaccines (Prestige, Intervet; Calvenza, Boehringer Ingelheim; Innovator, Fort Dodge) and one MLV vaccine (Rhinomune, Pfizer) for the prevention of respiratory disease induced by EHV-1 and -4. In Europe, Duvaxyn (Fort Dodge), an inactivated vaccine, is licensed to prevent both respiratory disease and abortion.

Viral shedding after infection with EHV-1 is reduced in horses vaccinated with inactivated vaccines that induce high serum titers of virus neutralizing (VN) antibody (Moore and Koonse, 1978; Burrows et al., 1984; Heldens et al., 2001). Of the available inactivated vaccines, Calvenza, and both vaccines marketed for preventing abortion (Pneumabort K-1B and Prodigy) stimulate higher levels of VN antibody than do other multi-component vaccines against respiratory disease (Holmes et al., 2006). The

potency of vaccines protective against abortion is associated with the stimulation of VN antibody and appears related to their high antigenic mass relative to that of the respiratory disease vaccines. Furthermore, the carboxy-polymer adjuvant is likely to be an important contributor to the potency of Calvenza, a vaccine of lower antigenic mass than the abortion vaccines. Even though both abortion vaccines are inactivated, they have recently been shown to induce interferon-gamma production, suggesting activation of a T-cell immune response (Holmes et al., 2006).

Whereas there is good evidence that inactivated EHV-1 vaccines that stimulate high levels of VN antibody are capable of reducing viral shedding and the incidence and severity of respiratory disease and abortion in both 'field' and experimental settings, compelling evidence for their efficacy in preventing EHM is lacking. Of the few published studies 2/6 (33.3%) of non-vaccinated control pregnant mares developed neurological disease and 3/6 (50%) aborted when challenged with the Army 183 strain of EHV-1 in a study assessing the protective efficacy of Pneumabort K-1B against abortion (Moore and Koonse, 1978). In contrast, none of the 11 mares vaccinated twice with Pneumabort K-1B 62 days apart developed neurological disease and 18% (2/11) aborted when challenged with the Army 183 strain by nasal spray 15 days after the second vaccination (Moore and Koonse, 1978). Although a shorter mean duration of viral shedding was observed in vaccinated than in control mares (0.72 relative to 3.5 days), statistical analysis of the significance of apparent differences between the two groups with regard to viral shedding and the development of neurological signs post-challenge was not carried out. Interestingly, the Army 183 strain of EHV-1 has recently been shown to carry the D752 polymerase gene mutation associated with an increased risk of inducing neurological disease (Perkins et al., 2008).

In contrast to the findings with inactivated vaccines, the significant attenuating effect of vaccination with Rhinomune MLV on viral shedding post challenge does not appear to be dependent on induction of high levels of VN, again providing circumstantial evidence for the importance of cellular and local responses in reducing viral shedding (Goodman et al., 2006). Five horses challenged with the neuropathogenic Findlay 03 strain of EHV-1 by aerosol 2 weeks after completion of a two-dose immunization series with Rhinomune shed significantly less virus for a substantially shorter period than did a group of five unvaccinated control horses and a group of five horses vaccinated with a low antigenic mass inactivated EHV-1/-4 vaccine (Goodman et al., 2006). Only 1/5 Rhinomune-vaccinated horses shed virus transiently after challenge whereas all five horses in each of the other groups shed virus. In addition, none of the five Rhinomune-vaccinated horses developed neurological signs after challenge, whereas 3/5 (60%) horses in each of the other two groups did. All horses used in this study were mature adults aged from 3 to 10 years old and were presumably not naïve to

EHV-1 infection, even though serum EHV-1 VN antibody titers were <24 in all animals prior to vaccination.

While the results of these challenge studies are promising and constitute a valuable contribution to the literature, the low numbers of horses used, the failure of either vaccine to prevent infection or significantly reduce the level of viremia, the lack of statistical significance of the results pertaining to the prevention of neurological signs, and the well-known difficulties encountered in accomplishing a consistent and reproducible challenge model for neurologic EHM justify caution in their interpretation. However, the significant reduction in viral shedding observed in vaccinated horses provides reasonable justification for booster vaccination of non-exposed horses at risk for infection in order to reduce viral shedding in the event of exposure to EHV-1. By enhancing herd immunity, it is hoped that the level of infectious virus circulating in the at-risk population and, in turn, the risk of individual horses in the population developing disease, will be reduced (Kohn and Fenner, 1987). This approach also relies on the assumption that the immune system of most mature horses has been primed by prior exposure to EHV-1 antigens through 'field' infection or vaccination and can therefore be boosted within 7–10 days of administration of a single dose of vaccine. Although the validity of this approach has not been critically evaluated for the prevention of EHM, its implementation seems rational when faced with one or more horses with confirmed clinical EHV-1 infection of any form.

Whereas booster vaccination of horses that are likely to have been exposed is not recommended, it is rational to booster vaccinate non-exposed horses, as well as those that must enter the premises, if they have not already been vaccinated against EHV-1 during the previous 90 days. Use of Rhinomune MLV or one of the inactivated EHV-1 vaccines known to stimulate high circulating titers of VN antibody appears justified in this context. Horse owners must develop an understanding of the concept of boosting herd immunity to help protect individual horses rather than having an (as yet unattainable) expectation that the attending veterinarian can reliably protect an individual horse from developing potentially fatal EHM by administering one of the currently available vaccines. At the present time, a combination of appropriate biosecurity and regular vaccination is likely to reduce the risk of acquiring infection.

Intensive research to develop more efficacious EHV-1 vaccines has been ongoing at multiple centers around the world for many years. In addition to improved adjuvants and delivery routes, novel technologies currently under investigation include the use of vaccine vectors such as canarypox, baculovirus, or vaccinia to deliver the EHV-1 glycoproteins gB, gC, and gD or the immediate early gene, and the use of DNA vaccines that deliver genes encoding these same glycoproteins, together with candidate CTL epitopes (Foote et al., 2005; Minke et al., 2006; Paillot et al., 2006; Soboll et al., 2006; Slater, 2007). In addition, promising results have been obtained using an attenuated live virus vaccine based on the temperature sensitive and host

range mutant clone 147 of EHV-1. This vaccine is novel in that a low dose administered intranasally replicated in the target species and conferred exceptional protection against respiratory disease, virus shedding, viremia and abortion following a severe EHV-1 challenge (Patel et al., 2003a,b, 2004). It is claimed that this intranasal MLV also protects against less common manifestations of EHV-1 infection, such as paresis and jaundice.

Biosecurity

There are significant difficulties in applying accepted prevention and control methods to EHV-1 infection in horses given that infection often occurs early in life and animals tend to harbor the virus for years. Such features make the diagnostic testing of asymptomatic horses unproductive. Secondly, the known tendency of the virus for recrudescence during periods of stress makes the identification of probable sources of infection extremely problematic. The following strategies are necessary to help prevent the introduction of EHV-1 and to control the spread of this virus during neurological and non-neurological outbreaks.

Strategies to prevent EHM in veterinary clinics

To prevent EHM within veterinary clinics and hospitals, all horses presenting with significant fevers and non-specific clinical signs that may or may not include neurological signs should be strictly isolated until a diagnosis is secured. Such an approach can prevent the later quarantine of an entire hospital should EHV-1 infection be diagnosed subsequently. The blood and nasal secretions of suspect horses should be tested repeatedly by RT-PCR for EHV-1, and other infectious agents, until these tests and accompanying clinical signs confirm or rule out active EHV-1 infection. Once EHV-1 infection is confirmed, strict isolation procedures and secondary quarantine of both the clinic and the source stable of the particular horse should be employed (see below).

Strategies to prevent EHM on stables and farms

All newly arrived horses should be isolated for at least 3 weeks. Foot-baths, boot covers and coveralls should be provided and adequately maintained for sanitary purposes. Separate equipment, tack, bedding and feedstuffs should be used in the care of these animals. Grooms and other personnel should be instructed to work with these animals last in the course of their daily routine. Exercise periods should be confined to a time when other horses are not present in the training areas and riders should wear protective clothing and clean and thoroughly disinfect their boots, tack and hands after contact with such animals. Similarly visitors from other horse facilities should be instructed to park their cars at a distance from horse barns and stables and wear clean clothes and shoes or shoe covers and protective

clothing provided by the stable. Horses returning from shows or extended traveling events should be isolated according to their particular circumstances. Minimum isolation precautions include the prevention of fomite transmission through 'nose to nose' contact or the indirect transmission of infective nasal secretions by mechanical transmission through stable employees or horse owners. All horse vans and trailers should be thoroughly cleaned and disinfected after use.

Strategies to prevent EHM following equine athletic events

Prevention of EHM following horse shows, races or other athletic events is problematic. While the requirement of an 'active vaccination status' prior to admittance and during extended stays at such events may lessen the probability of outbreaks of the respiratory form of EHV-1 infection, no vaccine currently offers protection against the development of EHM. Consequently, the effectiveness of any such strategy in this context is questionable. Since the positive predictive value of PCR testing for EHV-1 infection in asymptomatic horses is very low (Pusterla et al., 2008b), the requirement of a negative test prior to entry to an equine athletic event has very little merit. Likewise, the testing of normal and unexposed horses stabled on the grounds of an event during an outbreak is not recommended. The high percentage of horses known to have EHV-1 infection at any given time, combined with its proclivity to recrudescence, render the testing of asymptomatic horses a confusing and mostly futile exercise.

Thus, the examination of newly arrived horses for clinical signs of disease, including twice daily assessment of rectal temperature, must for the time being remain the most effective tool in determining possible sources of virus introduction.

Strategies for control during outbreaks of EHM

Following the identification of a horse with clinical signs consistent of EHM (such as fever, nasal discharge and the acute onset of neurological deficits) measures must be instituted immediately to confirm the diagnosis and control disease spread. It is known that the nasal secretions of horses with EHM contain large amounts of replicating virus and these secretions in particular contribute to the spread of disease to other susceptible individuals. As a consequence, horses suspected of having EHM must be removed from the stable environment as quickly as possible and placed in strict isolation. Failure to remove these animals facilitates the continued viral contamination of the environment and contributes to the spread of disease.

Attempts to prevent the spread of EHV-1 infection to additional horses without the removal and isolation of sick horses is ineffective (N. Pusterla, personal communication). Clinically affected horses should remain in strict quarantine until such time as they are proven either not to have EHV-1

infection or to have fully recovered and have been shown to be asymptomatic for 21 days.

Horses known to have had intimate contact with a suspected EHM case should be maintained in their existing barns and segregated from other horses during exercise periods until a diagnosis is made. Once confirmed, appropriate quarantine restricting the movement of all potentially exposed horses is necessary to prevent the spread of disease to other locations.

Aerosol transmission is considered less important than direct contact or spread of secretions on fomites between horses by handlers (N. Pusterla, personal communication). These procedures may begin with the focal quarantine of individuals in the immediate area of exposure, such as a single barn or other unit of housing within a facility. Horses in the immediate focal contact area of the clinically affected (index) individual should be monitored twice daily for fever and, if found to be febrile, tested for EHV-1 infection by PCR. Because of the known tendency for latency and recrudescence with EHV-1 infection, contact horses not exhibiting fever or clinical signs should not be tested with PCR methods, since the results obtained may not be related to disease transmission (see above). Since stress may play a role in eliciting the onset of clinical signs, horses stabled in areas of known exposure should not be subjected to strenuous physical exercise or long-distance transport until their health status is determined.

If after focal quarantine measures, additional clinically ill or EHV-1 positive horse(s) are identified at other locations within the facility, additional quarantine of exposed horses should be instituted and the area under quarantine may be expanded to include other affected barns or the entire stable area. An optimum strategy is the imposition of a series of focal quarantine procedures in an expanding series of 'concentric rings' of disease control.

Individual animals that have tested positive for EHV-1 infection within the designated quarantine area, whether symptomatic or not, should be periodically retested until disease is confirmed or eliminated based on lack of clinical signs and a negative PCR test result. Quarantine should be maintained until absence of further clinical cases and positive tests from exposed horses suggest no new cases are occurring. At this point areas of the facility under focal quarantine may have their restrictions rescinded in a reverse concentric ring approach.

Thus, early recognition of suspected cases and the close monitoring of high risk horses represent the most reliable measures of preventing outbreaks of EHM. Isolating horses with suspected EHM until a diagnosis is confirmed is recommended to prevent the exposure of susceptible horses.

Conclusions

Although EHM is a relatively uncommon manifestation of EHV-1 infection, it can cause devastating losses during outbreaks, as recently experienced at riding schools, race-

tracks and veterinary hospitals throughout North America and Europe (Kohn et al., 2006; Henninger et al., 2007). These outbreaks have highlighted the contagious nature of EHV-1 infection and the importance of rapid and reliable detection methods. The traditional approach of virus isolation has been supplanted in recent years by more sensitive and rapid molecular-based detection techniques.

Ante-mortem diagnosis of EHM relies mainly on the PCR detection of EHV-1 in nasal secretions and blood. Traditional qualitative PCR assays should not be used in support of a diagnosis of EHM since such assays are unable to differentiate between lytic and latent infection. Alternatively, novel quantitative PCR platforms, such as RT-PCR, should be used as these can determine the amount of virus present in blood and nasal secretions, a direct measure of the level of viremia and viral shedding, respectively. Further, molecular characterization of the viral state (lytic versus latent) is currently possible by the detection of transcripts of 'late' genes. These novel approaches, combined with new assays that can determine the viral genotype (neurotropic versus non-neurotropic), may help equine practitioners determine the risk of exposure of other horses and to implement appropriate management practices to minimize disease spread.

Management of horses affected by EHM must be aimed at supportive nursing, nutritional care and reducing CNS inflammation. Synthetic purine nucleoside analogs, such as valacyclovir and acyclovir, with inhibitory activity against several human herpesviruses, have recently been used in the treatment and prevention of EHV-1 infection. Horses exhibiting sudden and severe neurological signs consistent with a diagnosis of EHM pose a definite risk to the surrounding horse population. Consequently, early intervention to prevent the spread of infection is required.

Disease control measures, such as isolation of affected animals, segregation and monitoring of exposed horses and quarantine measures, should be established in order to prevent the spread of the virus. While there are several vaccines available against both the respiratory and abortifacient forms of EHV-1 infection, currently no vaccines are protective against the neurological strain of the virus.

Conflict of interest statement

None of the authors of this paper has a financial or personal relationship with other people or organizations that could inappropriately influence or bias the content of the paper.

References

- Adair, J.C., Gold, M., Bond, R.E., 1994. Acyclovir neurotoxicity: clinical experience and review of the literature. *Southern Medical Journal* 87, 1227–1231.
- Allen, G.P., 2007. Development of a real-time polymerase chain reaction assay for rapid diagnosis of neuropathogenic strains of equine herpesvirus-1. *Journal of Veterinary Diagnostic Investigation* 19, 69–72.

- Allen, G.P., Breathnach, C.C., 2006. Quantification by real-time PCR of the magnitude and duration of leukocyte-associated viremia in horses infected with neuropathogenic versus non-neuropathogenic strains of EHV-1. *Equine Veterinary Journal* 38, 252–257.
- Allen, G.P., Bryans, J.T., 1986. Molecular epizootiology, pathogenesis, and prophylaxis of equine herpesvirus-1 infection. *Progress in Veterinary Microbiology and Immunology* 2, 78–144.
- Ballagi-Pordany, A., Klingeborn, B., Flensburg, J., Belak, S., 1990. Equine herpesvirus type 1: detection of viral DNA sequences in aborted fetuses with the polymerase chain reaction. *Veterinary Microbiology* 22, 373–381.
- Bentz, B.G., Maxwell, L.K., Erkert, R.S., Royer, C.M., Davis, M.S., MacAllister, C.G., Clarke, C.R., 2006. Pharmacokinetics of acyclovir after single intravenous and oral administration to adult horses. *Journal of Veterinary Internal Medicine* 20, 589–594.
- Bentz, B.G., Maxwell, L.K., Bourne, D.W.A., Erkert, R.S., 2007. Pharmacokinetics of valacyclovir in the adult horse. In: *Proceedings of the 25th Annual Meeting of the American College of Veterinary Internal Medicine*, Seattle, USA, p. 601.
- Blythe, L.L., Mattson, D.E., Lassen, E.D., Craig, A.M., 1985. Antibodies against equine herpesvirus 1 in the cerebrospinal fluid in the horse. *Canadian Veterinary Journal* 26, 218–220.
- Borchers, K., Slater, J., 1993. A nested PCR for the detection and differentiation of EHV-1 and EHV-4. *Journal of Virology Methods* 45, 331–336.
- Burrows, R., Goodridge, D., Denyer, M.S., 1984. Trials of an inactivated equid herpesvirus 1 vaccine: challenge with a subtype 1 virus. *Veterinary Record* 114, 369–374.
- Crabb, B.S., Studdert, M.J., 1993. Epitopes of glycoprotein G of equine herpesviruses 4 and 1 located near the C termini elicit type-specific antibody responses in the natural host. *Journal of Virology* 67, 6332–6338.
- Crabb, B.S., MacPherson, C.M., Reubel, G.H., Browning, G.F., Studdert, M.J., Drummer, H.E., 1995. A type-specific serological test to distinguish antibodies to equine herpesviruses 4 and 1. *Archives of Virology* 140, 245–258.
- Diallo, I.S., Hewitson, G., Wright, L., Rodwell, B.J., Corney, B.G., 2006. Detection of equine herpesvirus type 1 using a real-time polymerase chain reaction. *Journal of Virology Methods* 131, 92–98.
- Donaldson, M.T., Sweeney, C.R., 1998. Herpesvirus myeloencephalopathy in horses: 11 cases (1982–1996). *Journal of the American Veterinary Medical Association* 213, 671–675.
- Drummer, H.E., Reynolds, A., Studdert, M.J., MacPherson, C.M., Crabb, B.S., 1995. Application of an equine herpesvirus 1 (EHV1) type-specific ELISA to the management of an outbreak of EHV1 abortion. *Veterinary Record* 136, 579–581.
- Edington, N., Bridges, C.G., Patel, J.R., 1986. Endothelial cell infection and thrombosis in paralysis caused by equid herpesvirus-1: equine stroke. *Archives of Virology* 90, 111–124.
- Elia, G., Decaro, N., Martella, V., Campolo, M., Desario, C., Lorusso, E., Cirone, F., Buonavoglia, C., 2006. Detection of equine herpesvirus type 1 by real time PCR. *Journal of Virology Methods* 133, 70–75.
- Foote, C.E., Love, D.N., Gilkerson, J.R., Rota, J., Trevor-Jones, P., Ruitenber, K.M., Wellington, J.E., Whalley, J.M., 2005. Serum antibody responses to equine herpesvirus 1 glycoprotein D in horses, pregnant mares and young foals. *Veterinary Immunology and Immunopathology* 105, 47–57.
- Friday, P.A., Scarratt, W.K., Elvinger, F., Timoney, P.J., Bonda, A., 2000. Ataxia and paresis with equine herpesvirus type 1 infection in a herd of riding school horses. *Journal of Veterinary Internal Medicine* 14, 197–201.
- Garré, B., van der Meulen, K., Nugent, J., Neyts, J., Croubels, S., De Backer, P., Nauwynck, H., 2007a. In vitro susceptibility of six isolates of equine herpesvirus 1 to acyclovir, ganciclovir, cidofovir, adefovir, PMEDAP and foscarnet. *Veterinary Microbiology* 122, 43–51.
- Garré, B., Shebany, K., Gryspeerdt, A., Baert, K., van der Meulen, K., Nauwynck, H., Deprez, P., De Backer, P., Croubels, S., 2007b. Pharmacokinetics of acyclovir after intravenous infusion of acyclovir and after oral administration of acyclovir and its prodrug valacyclovir in healthy adult horses. *Antimicrobial Agents and Chemotherapy* 51, 4308–4314.
- Goodman, L.B., Wagner, B., Flaminio, M.J., Sussman, K.H., Metzger, S.M., Holland, R., Osterrieder, N., 2006. Comparison of the efficacy of inactivated combination and modified-live virus vaccines against challenge infection with neuropathogenic equine herpesvirus type 1 (EHV-1). *Vaccine* 24, 3636–3645.
- Heldens, J.G., Hannant, D., Cullinane, A.A., Prendergast, M.J., Mumford, J.A., Nelly, M., Kydd, J.H., Weststrate, M.W., van den Hoven, R., 2001. Clinical and virological evaluation of the efficacy of an inactivated EHV1 and EHV4 whole virus vaccine (Duvaxyn EHV1.4). Vaccination/challenge experiments in foals and pregnant mares. *Vaccine* 19, 4307–4317.
- Henninger, R.W., Reed, S.M., Saville, W.J., Allen, G.A., Hass, G.F., Kohn, C.W., Sofaly, C., 2007. Outbreak of neurologic disease caused by equine herpesvirus-1 at a university equestrian center. *Journal of Veterinary Internal Medicine* 21, 157–165.
- Holmes, M.A., Townsend, H.G., Kohler, A.K., Hussey, S., Breathnach, C., Barnett, C., Holland, R., Lunn, D.P., 2006. Immune responses to commercial equine vaccines against equine herpesvirus-1, equine influenza virus, eastern equine encephalomyelitis, and tetanus. *Veterinary Immunology and Immunopathology* 111, 67–80.
- Hussey, S.B., Clark, R., Lunn, K.F., Breathnach, C., Soboll, G., Whalley, J.M., Lunn, D.P., 2006. Detection and quantification of equine herpesvirus-1 viremia and nasal shedding by real-time polymerase chain reaction. *Journal of Veterinary Diagnostic Investigation* 18, 335–342.
- Jackson, T.A., Kendrick, J.W., 1971. Paralysis of horses associated with equine herpesvirus 1 infection. *Journal of the American Veterinary Medical Association* 158, 1351–1357.
- Jackson, T.A., Osburn, B.I., Cordy, D.R., Kendrick, J.W., 1977. Equine herpesvirus 1 infection of horses: studies on the experimentally induced neurologic disease. *American Journal of Veterinary Research* 38, 709–719.
- Keane, D.P., Little, P.B., Wilkie, B.N., Artsob, H., Thorsen, J., 1988. Agents of equine viral encephalomyelitis: correlation of serum and cerebrospinal fluid antibodies. *Canadian Journal of Veterinary Research* 52, 229–235.
- Kirisawa, R., Endo, A., Iwai, H., Kawakami, Y., 1993. Detection and identification of equine herpesvirus-1 and -4 by polymerase chain reaction. *Veterinary Microbiology* 36, 57–67.
- Klingeborn, B., Dinter, Z., Hughes, R.A., 1983. Antibody to neuritic myelin protein P2 in equine paresis due to equine herpesvirus 1. *Zentralblatt für Veterinärmedizin B* 30, 137–140.
- Kohn, C.W., Fenner, W.R., 1987. Equine herpes myeloencephalopathy. *Veterinary Clinics of North America Equine Practice* 3, 405–419.
- Kohn, C.W., Reed, S.M., Sofaly, C.D., Henninger, R.W., Saville, W.J., Allen, G.P., Premanadan, C., 2006. Transmission of EHV-1 in horses with EHV-1 myeloencephalopathy: implications for biosecurity and review. *Clinical Techniques in Equine Practice* 5, 60–66.
- Lawrence, G.L., Gilkerson, J., Love, D.N., Sabine, M., Whalley, J.M., 1994. Rapid, single-step differentiation of equid herpesviruses 1 and 4 from clinical material using the polymerase chain reaction and virus-specific primers. *Journal of Virology Methods* 47, 59–72.
- Leutenegger, C.M., Madigan, J.E., Mapes, S., Thao, M., Estrada, M., Pusterla, N., 2008. Detection of EHV-1 neuropathogenic strains using real-time PCR in the neural tissue of horses with myeloencephalopathy. *Veterinary Record* 162, 688–689.
- McCartan, C.G., Russell, M.M., Wood, J.L., Mumford, J.A., 1995. Clinical, serological and virological characteristics of an outbreak of paresis and neonatal foal disease due to equine herpesvirus-1 on a stud farm. *Veterinary Record* 136, 7–12.
- Minke, J.M., Fischer, L., Baudu, P., Guigal, P.M., Sindle, T., Mumford, J.A., Audonnet, J.C., 2006. Use of DNA and recombinant canarypox viral (ALVAC) vectors for equine herpes virus vaccination. *Veterinary Immunology and Immunopathology* 111, 47–57.

- Moore, B.O., Koonse, H.J., 1978. Inactive equine herpesvirus I vaccine – Pneumaboar-K. In: Proceedings of the 24th Annual Meeting of the American Association of Equine Practitioners, St. Louis, USA, pp. 75–79.
- Mumford, J.A., 1984. The development of diagnostic techniques for equine viral diseases. *Veterinary Annals* 24, 182–189.
- Mumford, J.A., 1985. Equine herpesvirus 1 (EHV-1) latency: more questions than answers. *Equine Veterinary Journal* 17, 340–342.
- Murray, M.J., del Piero, F., Jeffrey, S.C., Davis, M.S., Furr, M.O., Dubovi, E.J., Mayo, J.A., 1998. Neonatal equine herpesvirus type 1 infection on a thoroughbred breeding farm. *Journal of Veterinary Internal Medicine* 12, 36–41.
- Nugent, J., Birch-Machin, I., Smith, K.C., Mumford, J.A., Swann, Z., Newton, J.R., Bowden, R.J., Allen, G.P., Davis-Poynter, N., 2006. Analysis of equine herpesvirus type 1 strain variation reveals a point mutation of the DNA polymerase strongly associated with neuropathogenic versus non-neuropathogenic disease outbreaks. *Journal of Virology* 80, 4047–4060.
- Ostlund, E.N., 1993. The equine herpesviruses. *Veterinary Clinics of North America Equine Practice* 9, 283–294.
- Paillot, R., Ellis, S.A., Daly, J.M., Audonnet, J.C., Minke, J.M., Davis-Poynter, N., Hannant, D., Kydd, J.H., 2006. Characterisation of CTL and IFN-gamma synthesis in ponies following vaccination with a NYVAC-based construct coding for EHV-1 immediate early gene, followed by challenge infection. *Vaccine* 24, 1490–1500.
- Paradis, M.R., 1996. Equine herpesvirus. In: Smith, B.A. (Ed.), *Large Animal Internal Medicine*, second ed. Mosby, St. Louis, USA, pp. 587–588.
- Patel, J.R., Heldens, J., 2005. Equine herpesviruses 1 (EHV-1) and 4 (EHV-4) – epidemiology, disease and immunoprophylaxis: a brief review. *The Veterinary Journal* 170, 14–23.
- Patel, J.R., Földi, J., Bateman, H., Williams, J., Didlick, S., Stark, R., 2003a. Equid herpesvirus (EHV-1) live vaccine strain C147: efficacy against respiratory diseases following EHV types 1 and 4 challenges. *Veterinary Microbiology* 92, 1–17.
- Patel, J.R., Bateman, H., Williams, J., Didlick, S., 2003b. Derivation and characterisation of a live equid herpes virus-1 (EHV-1) vaccine to protect against abortion and respiratory disease due to EHV-1. *Veterinary Microbiology* 91, 23–39.
- Patel, J.R., Didlick, S., Bateman, H., 2004. Efficacy of a live equine herpesvirus-1 (EHV-1) strain C147 vaccine in foals with maternally-derived antibody: protection against EHV-1 infection. *Equine Veterinary Journal* 36, 447–451.
- Peet, R.L., Coackley, W., Smith, V.W., Main, C., 1978. Equine abortion associated with herpesvirus. *Australian Veterinary Journal* 44, 151.
- Perkins, G.A., Goodman, L.B., Tsujimura, K., Van de Walle, G.R., Kim, S.G., Dubovi, E., Osterrieder, N., 2008. Investigation of neurologic equine herpes virus 1 epidemiology from 1984 to 2007. In: Proceedings of the 26th Annual Meeting of the American College of Veterinary Internal Medicine, San Antonio, USA. p. 819.
- Pusterla, N., Leutenegger, C.M., Wilson, W.D., Watson, J.L., Ferraro, G.L., Madigan, J.E., 2005. Equine herpesvirus-4 kinetics in peripheral blood leukocytes and nasopharyngeal secretions in foals using quantitative real-time TaqMan PCR. *Journal of Veterinary Diagnostic Investigation* 17, 578–581.
- Pusterla, N., Wilson, W.D., Conrad, P.A., Barr, B.C., Ferraro, G.L., Daft, B.M., Leutenegger, C.M., 2006. Cytokine gene signatures in neural tissue of horses with equine protozoal myeloencephalitis or equine herpes type 1 myeloencephalopathy. *Veterinary Record* 159, 341–346.
- Pusterla, N., Mapes, S., Wilson, W.D., 2008a. Use of viral loads in blood and nasopharyngeal secretions for the diagnosis of EHV-1 infection in field cases. *Veterinary Record* 31, 728–729.
- Pusterla, N., Wilson, W.D., Mapes, S., Finno, C., Isbell, D., Arthur, R.M., Ferraro, G.L., 2008b. Characterization of viral loads, strain and state of equine herpesvirus-1 using real-time PCR in horses following natural exposure at a racetrack in California. *Veterinary Journal*. doi:10.1016/j.tvjl.2007.09.018, Epub ahead of print.
- Reed, S.M., Toribio, R.T., 2004. Equine herpesvirus 1 and 4. *Veterinary Clinics of North America Equine Practice* 20, 631–642.
- Rollinson, E.A., White, G., 1983. Relative sensitivities of acyclovir in vitro and in vivo. *Journal of Antimicrobial Chemotherapy* 12, 19–27.
- Schmidt, P., Meyer, H., Hübert, P., Hafner, A., Andiel, E., Grabner, A., Dahme, E., 1994. In situ hybridization for demonstration of equine herpesvirus type 1 DNA in paraffin wax-embedded tissues in its use in horses with disseminated necrotizing myeloencephalitis. *Journal of Comparative Pathology* 110, 215–225.
- Sharma, P.C., Cullinane, A.A., Onions, D.E., Nicolson, L., 1992. Diagnosis of equid herpesviruses-1 and -4 by polymerase chain reaction. *Equine Veterinary Journal* 24, 20–25.
- Slater, J., 2007. Equine herpesviruses. In: Sellon, D., Long, M. (Eds.), *Equine Infectious Diseases*. Saunders Elsevier, St. Louis, USA, pp. 134–153.
- Smith, K.O., Galloway, K.S., Hodges, S.L., Ogilvie, K.K., Radatus, B.K., Kalter, S.S., Heberling, R.L., 1983. Sensitivity of equine herpesviruses 1 and 3 in vitro to a new nucleoside analogue, 9-[[2-hydroxy-1-(hydroxymethyl)ethoxy]methyl] guanine. *American Journal of Veterinary Research* 44, 1032–1035.
- Soboll, G., Hussey, S.B., Whalley, J.M., Allen, G.P., Koen, M.T., Santucci, N., Fraser, D.G., Macklin, M.D., Swain, W.F., Lunn, D.P., 2006. Antibody and cellular immune responses following DNA vaccination and EHV-1 infection of ponies. *Veterinary Immunology and Immunopathology* 111, 81–95.
- Van Maanen, C., 2002. Equine herpesvirus 1 and 4 infections: an update. *Veterinary Quarterly* 24, 58–78.
- Van Maanen, C., Sloet van Oldruitenborgh-Oosterbaan, M.M., Damen, E.A., Derksen, A.G., 2001. Neurological disease associated with EHV-1-infection in a riding school: clinical and virological characteristics. *Equine Veterinary Journal* 33, 191–196.
- Wagner, W.N., Bogdan, J., Haines, D., Townsend, H.G., Misra, V., 1992. Detection of equine herpesvirus and differentiation of equine herpesvirus type 1 from type 4 by the polymerase chain reaction. *Canadian Journal of Microbiology* 38, 1193–1196.
- Whitwell, K.E., Gower, S.M., Smith, K.C., 1992. An immunoperoxidase method applied to the diagnosis of equine herpesvirus abortion, using conventional and rapid microwave techniques. *Equine Veterinary Journal* 24, 10–12.
- Wilkins, P.A., 2004. Acyclovir in the treatment of EHV-1 myeloencephalopathy. In: Proceedings of the 22nd Annual Meeting of the American College of Veterinary Internal Medicine, Minneapolis, USA, pp. 170–172.
- Wilkins, P.A., Papich, M., Sweeney, R., 2005. Pharmacokinetics of acyclovir in adult horses. *Journal of Veterinary Emergency and Critical Care* 15, 174–178.
- Wilson, J.H., 1991. Neurological syndrome of rhinopneumonitis. In: Proceedings of the Ninth Annual Meeting of the American College of Veterinary Internal Medicine, San Diego, USA, pp. 419–421.
- Wilson, W.D., 1997. Equine herpesvirus 1 myeloencephalopathy. *Veterinary Clinics of North America Equine Practice* 13, 53–72.
- Wilson, W.D., Pusterla, N., 2004. Equine herpesvirus 1 myeloencephalopathy. In: Reed, S.M., Bayly, W.M., Sellon, D.C. (Eds.), *Equine Internal Medicine*. Saunders Elsevier, St. Louis, USA, pp. 617–628.